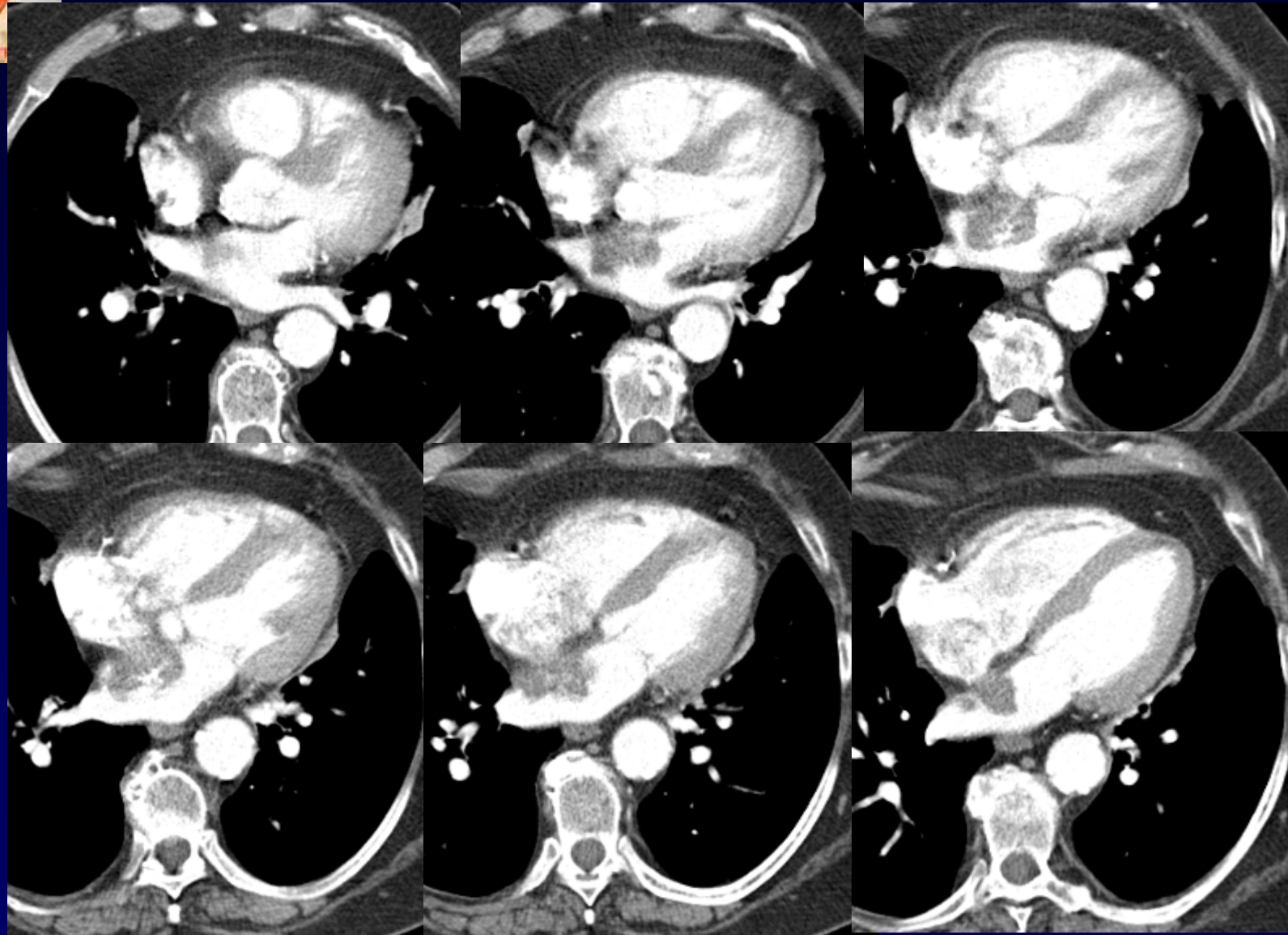
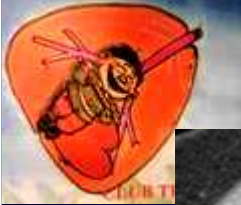


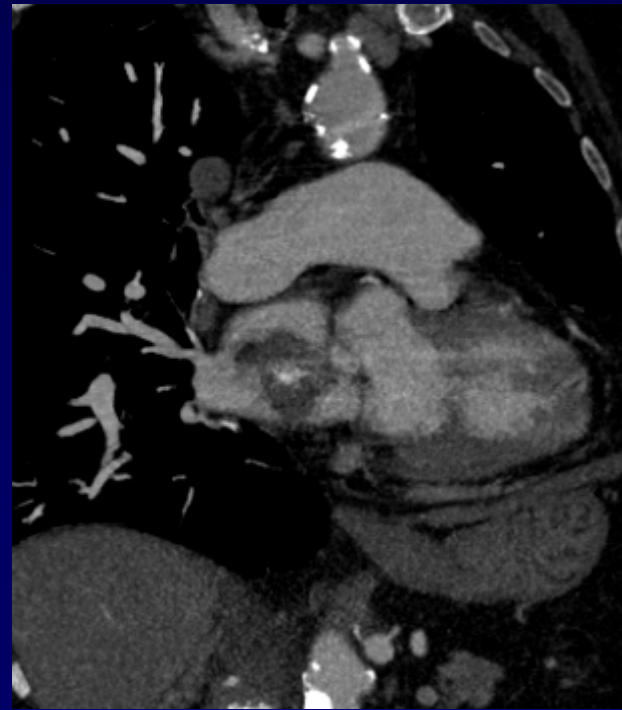
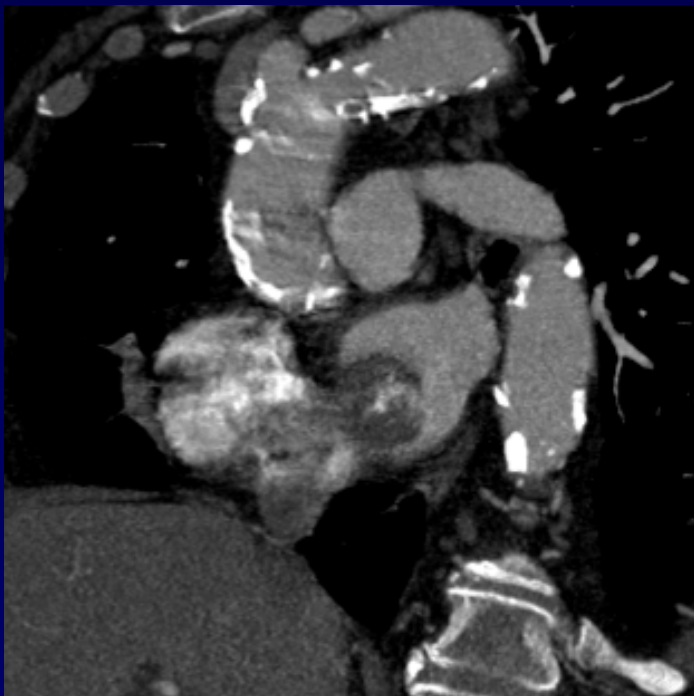
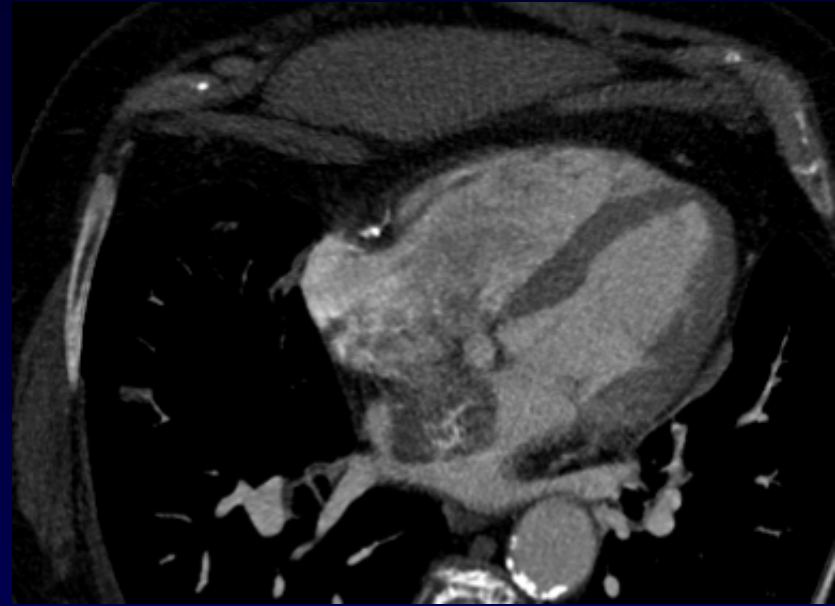
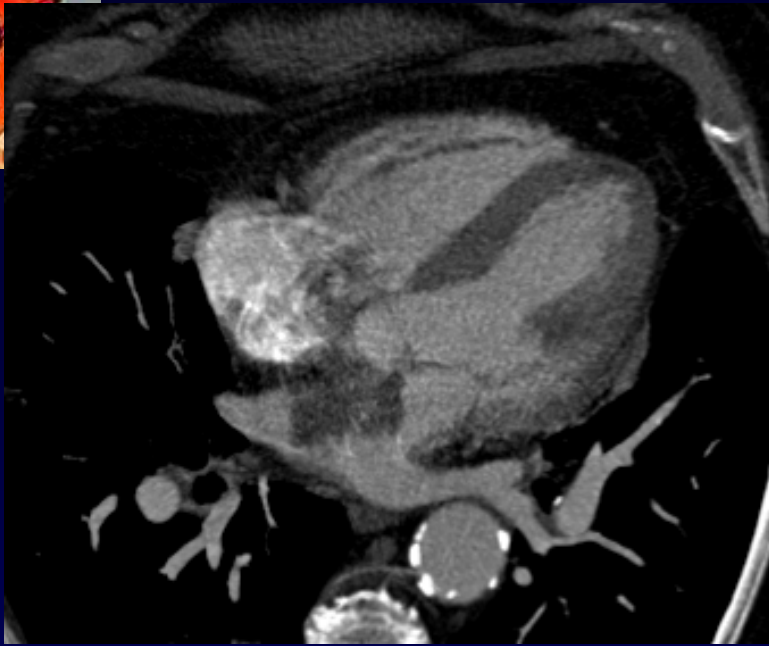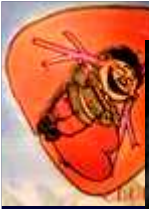

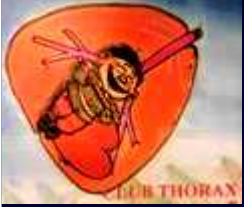
Dossier 8

**A Khalil
MF Carette**

**Femme de 79 ans
Bilan d'hémoptysie minime**







Diagnostic ?



Diagnostic

Myxome de l'oreillette gauche de découverte fortuite sur la TDM

Cardiovasculaire - Tumoral